



PREMORBID BRAIN VOLUME AGAINST ALZHEIMER'S DISEASE USING MULTIMODAL BIG MEDICAL DATA ANALYSIS

Padmini Mansingh¹, Binod Kumar Pattanayak¹, Bibudhendu Pati², Bassam Elzaghmouri³ and Ahmad Khader Habboush³

¹Department of Computer Science and Engineering, Institute of Technical Education and Research (ITER), Siksha 'O' Anusandhan (Deemed to be University), Bhubaneswar, Odisha, India

²Department of Computer Science, Rama Devi Women's University, Bhubaneswar, Odisha, India

³Faculty of Information Technology, Jerash University, Jerash, Jordan

E-Mail: padminimansingh@gmail.com, binodpattanayak@soa.ac.in, patibibudhendu@gmail.com, b.el-zaghmouri@jpu.edu.jo, ahmad_ram2001@jpu.edu.jo

ABSTRACT

Abstract Alzheimer's disease is a neurological ailment in which memory loss and cognitive impairment are brought on by the death of brain cells. Alzheimer's disease is the most prevalent kind of dementia affecting people aged 60 and above. It is a neurodegenerative type of dementia that starts in the middle and gets worse over time. Alzheimer's disease, epilepsy, multiple sclerosis, cancer, depression, and other brain illnesses can all be diagnosed using hippocampus segmentation. Medical pictures have had a significant impact on medicine, diagnosis, and treatment. One of the most crucial image processing techniques is called image segmentation. Our research focuses on measuring the volume concerning typical size by utilizing segmentation techniques. To comprehend the severity of progression in demented people, this study will look at the whole brain (WB), grey matter (GM), and hippocampal (HC) morphological variation and identify the significant biomarkers in MRI brain images. Pre-trained models can demonstrate hippocampal regions with significant severity differences for the considered classes of CN and AD. It is determined that the CNN model for the HC region produces better categorization for CN and AD with 98.2 percent accuracy each. The primary goal of the research was to identify size anomalies using several biochemical features of big medical data analysis.

Keywords: five big data analytics, deep learning, hippocampus segmentation.

1. INTRODUCTION

This Today's most challenging and developing field is medical image processing. The process of separating and partitioning a picture into components, or processes, is known as image segmentation. Image segmentation is the most crucial step in image processing. Confirmed by cognitive-behavioural tests, frequently followed by brain imaging. To quantify anatomical properties of the brain, analyse brain changes, designate sick regions, plan surgical operations, and carry out image-guided interventions, image segmentation is frequently employed in brain MRI analysis. Changes in the hippocampus could offer even more accurate early identification of changes in the hippocampus. Alzheimer's disease (AD), which causes 60 to 80 percent of instances of dementia, is the most frequent cause. A crucial temporal lobe structure for memory is the hippocampus. Early memory loss is accompanied by a decrease in the hippocampus and entorhinal cortex volume, which may indicate the development of MCI and AD. Measures of hippocampal atrophy from structural MRI are frequently utilized. Typically, morphological features can identify cerebrospinal fluid, white matter, and distinct grey spectra in brain imaging by detecting more subtle colors like white and different grey spectra. In medical diagnosis and therapy, medical images have become crucial. However, one of the main obstacles to MRI use is that the data volume is too huge for manual processing. Utilizing MRI has certain drawbacks, such as noise, intensity, homogeneities, limited contrast between specific tissues, and partial volume effects during segmentation tasks

Image segmentation is a method for extracting the region of interest automatically or semi-automatically (ROI). Partitioning the image into multiple regions is the major goal of some brain research projects. Alzheimer's disease is a neurological illness that frequently affects thinking and daily event recall. As Alzheimer's disease progresses, plaques and tangles tend to spread across the cortex. Beta-amyloid protein deposits, often known as plaques, accumulate in the gaps between nerve cells. Twisted tau protein fibres accumulate inside cells to form tangles. The brain's abnormalities can have a serious impact on the human body's regulation and functionality. Older theories suggest that a larger brain volume may offer a superior cerebral reserve against Alzheimer's disease. Contrary to cerebral volume, intracranial size measurement determines the maximum premorbid brain size, which shouldn't be impacted by atrophy brought on by neurodegeneration or aging [1]. The loss of brain cells is the primary cause of AD. The three stages of AD progression are mild, moderate, and severe. In patients with AD, suggest a method that maps the ventricular area and hippocampus for atrophy. They created a surface-based anatomical modeling technique to map the dynamic alterations in the ventricular and hippocampal regions. The proposed methodology involves comparative research on various segmentations and stages of Alzheimer's disease. Alzheimer's disease is a neurological illness that frequently affects thinking and daily event recall. As Alzheimer's disease progresses, plaques and tangles tend to spread across the cortex. In the gaps between nerve cells, a protein fragment known as beta-amyloid



accumulates, forming plaques. The loss of brain cells, which is the primary cause of AD, progresses mostly via four three phases, resulting in tangles, which are twisted fibers of a separate protein called tau that accumulates inside human cells. When doing image processing on digital images using computer algorithms, image segmentation is a vital and challenging phase. Using an image segmentation technique, an image is divided into meaningful sections with related qualities and characteristics. The primary goal of segmentation is simplification, or portraying an image in a form that makes sense and is simple to analyze. The initial stage in image analysis is image segmentation, which is essential. Based on the attributes of the image, local and global segmentation are divided into two types. In other terms, we may also argue that there are three ways to approach image segmentation: the region method, the edge approach, and data clustering. These segmentation techniques separate the image pixels according to their level of intensity. As has been previously theorised, a larger brain volume may provide a higher cerebral reserve against the effects of Alzheimer's disease. In contrast to cerebral volume, the maximal premorbid brain size should be unaffected by atrophy brought on by age-related neurodegeneration. The research's risk is the discovery of the disease's overall volume shrink. Due to nerve cell death and generalised tissue loss in the brain, AD causes shrinkage of brain tissue and enlargement of the ventricles, which hold cerebrospinal fluid. Pre-processing, CNN classification, and post-processing are the three primary steps in the detection of aberrant brain size. The primary goal of the research was to identify size anomalies using several biochemical features. The software pipelines for Statistical Parametric Mapping (SPM) and FreeSurfer (FS) most typically use T1-weighted images. In the past, many SPM and FS versions have been evaluated in terms of ICV estimates. This is a set of GMs and WM's strong contrast.

We outline the research's objectives in section II, and the background and purpose for the research are presented in section III, In section IV: contains an elaborative description of related works, section V: describes the Total Brain Volume and Intracranial Volume, and section VI: describes the Image Segmentation, section VII: elaborates on Brain MRI Imaging, section VIII: gives Methodology, section IX: elaborates on the measurements used in the calculation part, section X: gives the classification part, section XI: describe the experiment part, section XII: gives result part, section XIII: describe the discussion and the last section XIV: contribute the conclusion part.

2. OBJECTIVES

In general, morphological features can identify more subtle changes in the hippocampus, which may give even more sensitive detection of early changes in the hippocampus. Hippocampus atrophy assessments from structural MRI are extensively employed. This research's goal is to use deep learning techniques to categorize the AD and Normal Control (CN) groups based on the morphological characteristics of the hippocampus.

Alzheimer's disease (AD) is one of the brain disorders that worsen over time. Diagnosing Alzheimer's using image processing is a crucial yet difficult issue in modern medicine since noise makes image processing difficult. Total intracranial volume (TIV) measurement is frequently used in imaging investigations of cerebral regions in Alzheimer's disease to account for variations in premorbid brain size (AD). The decline of cognitive skills in neurodegenerative diseases is correlated with a drop in volume estimations in certain medical temporal lobe structures associated with memory. Several techniques have been developed during the last few decades for measuring the volume of the hippocampus that has atrophied due to illness. Our work is motivated by the necessity to use a different method, namely convolutional neural networks, to decrease the calculation time of automatic hippocampal segmentation.

3. BACKGROUND AND PURPOSE

For determining the extent of whole-brain shrinkage in conditions like Alzheimer's disease, dementia, and other neurodegenerative disorders, total brain volume and total intracranial volume are crucial measurements. Total brain volume and total intracranial volume can be accurately calculated using MRI imaging, which has several completely automated approaches that have been thoroughly tested. In general, MRI is more sensitive to finding anomalies in the brain in the early stages of the disease. To observe the severity variation in these places, pre-trained models are applied.

4. RELATED WORKS

Fuzzy approaches, neural networks, atlas methods, knowledge-based techniques, shape methods, variations, methods, and variation segmentation are some of the methodologies used today for classifying MR images. PD (proton density) weighted images are processed using a system that combines fuzzy-based techniques with multispectral analysis. T1 weighted, T2 weighted, and PD (proton density) images are used in MRIs. White matter and grey matter segmentation on MRI using various clustering techniques [2]. Based on the intensity and potential spatial value, the white matter and grey matter will be divided. The centroid value and FCM clustering method are used in the suggested mean clustering algorithm, which divides the image into two classes. It examines each feature in the image and produces accurate and forceful results developing a method for applying deep learning to segment the digital image. The technique is used to perform the segmentation, suggesting a method for mapping the atrophy of the ventricular and hippocampal regions in AD patients. A method of automatic image segmentation of a brain picture utilizing the SOM methodology [3]. Feature extraction has been applied in this work. This includes better accuracy at higher levels of intensity regions and noise compared to typical segmentation findings. For people with Alzheimer's disease, several researchers have developed and produced a variety of technical solutions for assistive wearable technology. The goal was to



research existing wearable assistive technologies and IoT-based technology advancements that are available to benefit caregivers and AD patients [4]. To map where dynamic changes, have a place, they devised a surface-based anatomical modeling technique. Environmental data is collected by a sensor network, gathered, and then transmitted to a web server via a cloud service in a four-layer IoT-based environmental monitoring system [5]. Noise data may make it difficult for researchers to address the issue by complicating a variety of fault tolerance provisioning approaches and fault tolerance in the cloud computing environment [6]. Changes can be made for the early diagnosis of sickness from several sources, including data from the environment and medical sources.

5. TOTAL BRAIN VOLUME AND INTRACRANIAL VOLUME

Total brain volume (TBV) and intracranial volume (ICV) are the two categories of brain volume that we concentrate our volume calculations on (ICV). Although there are other types of brain volume, investigations of the structure of the brain frequently employ TBV and ICV since they are the simplest to compute. TBV and ICV are defined differently in medical research articles, but for the purposes of this article, we'll use TBV to refer to the total amount of grey and white brain matter that isn't also found in the ventricles and ICV to refer to the total amount of grey and white brain matter that also includes the inner and outer cerebrospinal fluid spaces.

Total brain volume (TBV)

$$= \sum \text{gray matter volume} + \sum \text{white matter volume}$$

ventricular brain ratio

= the ratio of total ventricle area to total brain area
 Pre morbid brain size = volume of the brain affected AD

ICV was estimated as the result of adding the native voxel volume to the three subsequent instinctive space possibility pictures (GM, WM, and CSF). Due to earlier findings linking hippocampus volume to cognition, education, and gender, it was decided to examine how different normalizations affected the association with these variables. When performing morphometric analysis to account for head size in investigations of Alzheimer Disease, the intracranial volume (ICV) is a crucial normalisation parameter (AD) in Figure-1.

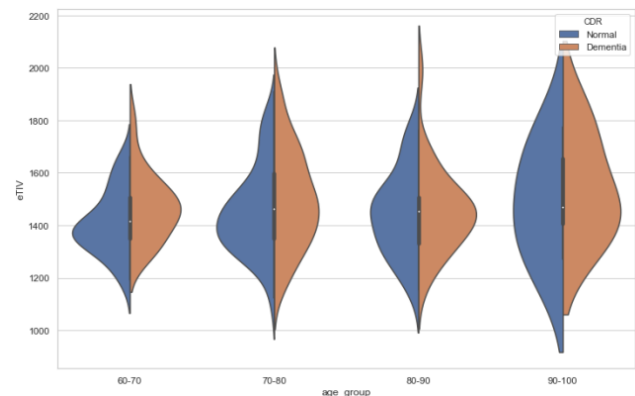


Figure-1. Estimated total intracranial volume vs age_group.

Hippocampal volumes on the left and right sides were divided by ICV from each corresponding method to achieve normalization.

Intracranial Volume (ICV)

$$= \sum \text{gray matter} + \sum \text{white matter} + \text{CSF} = \text{meninges} + \text{CSF} + \text{brain}$$

Plaques and tangles with these characteristics can be seen when the brain is examined. Your doctor may conduct blood tests to rule out any further possible reasons for disorientation and memory loss. Such as vitamin deficits or thyroid conditions. A quick mental status examination or a more comprehensive battery of tests can be used to evaluate one's memory and other cognitive abilities. By comparing one's mental function to that of people of a similar age and educational level, one can identify any outward signs of conditions other than Alzheimer's disease, such as tumors and trauma. Make decisions, communicate, and perform routine daily tasks. According to estimates, roughly 35% of down syndrome individuals in their 45 will get Alzheimer's disease. The slow brain cell death caused by Alzheimer's impairs memory and learning the diagnosis and treatment of many brain illnesses, including Alzheimer's disease, hippocampal segmentation is crucial. Both long-term memory and short-term memory depend on the hippocampus, which frequently shrinks in size and form when afflicted by disease [7]. The left and right hippocampal volumes measured by the first and second-raters had intraclass correlation coefficient (ICCs) of 0.83 and 0.87, respectively. The inter-rater reliability ICCs for the hippocampus volume measurements ranged from 0.77 to 0.91. However, manual segmentation still needs to be done by experts and takes time. For a while, approaches with execution times of hours per volume computation and about 0.9 Dice constituted the majority of the state-of-the-art in automated hippocampal segmentation [8]. FreeSurfer (Fischl, 2012), a tool used by doctors today to assist in segmentation but which takes hours to segment, is one notable example. It has a set of approaches for comprehensive brain segmentation. The information obtained from an MRI scan, which creates comprehensive



images of brain atrophy using radio waves and a strong magnetic field, is currently of little assistance in making diagnoses. Tests to measure the biochemical signs of disease processes in the brain are being developed by researchers. For individuals with early-onset Alzheimer's disease in their families before undergoing any tests, it is advised that you speak with a genetic counsel or about the advantages and disadvantages of genetic testing. The networks are trained in sagittal, coronal, and axial brain orientations. Large amounts of data with an increasingly high level of quality have also been made available because of improvements in brain MRI imaging.

Clinicians must manually extract crucial information from these enormous and complex MRI datasets, which is a tiresome and challenging task. Due to numerous inter- or intra-operator variability studies, this manual analysis is frequently time-consuming and prone to errors. To improve disease detection and testing, automated approaches had to be created to overcome the challenges of brain MRI data interpretation. The technique of dividing a digital image into different parts is called image segmentation. Typically, image segmentation is used to identify boundaries and objects in images (lines, curves, etc) in pictures. Image segmentation is the process of giving each pixel in an image a label so that each pixel may be identified.

6. IMAGE SEGMENTATION

One of the brain ailments that worsens year after year is Alzheimer's disease. The use of image processing to diagnose Alzheimer's disease is a significant but difficult subject in medical science because image processing is complicated by noise, low contrast, and other imaging difficulties. Medical image analysis uses a variety of techniques, such as pre-processing, feature extraction, image segmentation, and classification. Segmentation using a different approach was compared to the classification of AD using SVM and CNN. Image segmentation is the process of labelling each pixel in an image so that pixels with the same label have certain characteristics [9]. The important items or feature highlights must be categorically named. The result of segmentation is either a set of contours that show the boundaries of the homogenous regions or an image of labels identifying each one. The categorization of MRI data into distinct tissue types and the identification and description of distinct are fundamental elements of structural brain MRI analysis. The brain can be imaged in great detail using magnetic resonance imaging (MRI). The simultaneous segmentation of the hippocampus and amygdala provides the main relationship constraint. There are several different methods for segmenting photos. The issues with segmentation and classification are related because a classifier implicitly segments an image, whereas segmentation implies a classification. White matter (WM), grey matter (GM), and cerebrospinal fluid (CSF) are the three main tissue types in the case of brain MRIs. Each of these regions has distinct properties in terms of color, texture, and intensity. The majority of research on image segmentation has been on 2D pictures. If the data is

described in three dimensions (such as when it comes from a sequence of MRI pictures), each image "slice" is often segmented separately in a "slice-by-slice" fashion. Therefore, the creation of 3D segmentation algorithms is desired for better volumetric imaging segmentation. Medical image segmentation remains a complex and difficult subject even though several techniques have been suggested in this area. To reduce the over-segmentation scheme, a 2D merging was then performed. The analysis of what is being shown in the various levels. The brain MRI imaging was done on patients with Alzheimer's disease and control participants because the hippocampus is only present in the centre, reducing the time complexity of the process by not converting the complete image into a binary format. Using a specially created software system, the hippocampus was manually traced in native space and the orientation of consecutive sagittal slices going from the most posterior to the most anterior slice. First, features are extracted, then supplied to a classifier whose training process has no impact on the data's nature.

6.1 MANUAL SEGMENTATION

Manual segmentation is the process in which an image is manually segmented and labeled by a human operator (such as a skilled medical professional). When segmenting 3D volumetric imagery, this is often done "slice-by-slice." Segmentation is the process of splitting a picture into areas with comparable characteristics, such as brightness, contrast, color, texture, and grey level. Unsupervised segmentation techniques based on random walks, as proposed by C. Desrosiers, have been used to divide up an MRI picture of the brain. Basic segmentation and advanced segmentation are the two forms of segmentation.

It is challenging to automatically segment medical images since they are frequently complicated in nature and lack basic linear features. Additionally, the segmentation algorithm's output is impacted.

6.2 EDGE-BASED SEGMENTATION

The most popular approach of segmentation relies on the detection of edges, or borders, that demarcate different regions. The basis of the edge detection approach is the identification of discontinuities in the color, grayscale, etc. These edges frequently serve as the boundaries between objects. By using boundaries, this technique separates an image. Edge detectors based on gradient (derivative) functions include the Prewitt, Sobel, Roberts (1st derivative type), Laplacian (2nd derivative type), Canny, and Marr-Hilclrath edge detectors, to name just a few. Additionally, an edge chain made of the detected edges must be used to form the boundary.

Segmentation of a picture is accomplished to identify the closed borders. The ventricular zone is accurately located and stable, but noise from outside the region needs to be thresholded again. Edge-based detection utilizing Canny delivered proper output edges with decreased noise. The slice was much better with the active contour. The region growth algorithm has produced one of the best results. Initialization, which is dependent



on the core slice, is not automatic. In order to reduce the cost, we computed the singular value decomposition (SDV) of each slice using n as the number of decomposed images [10]. The result is a well-reconstructed image. The different types of edge techniques are described on Figure-2.

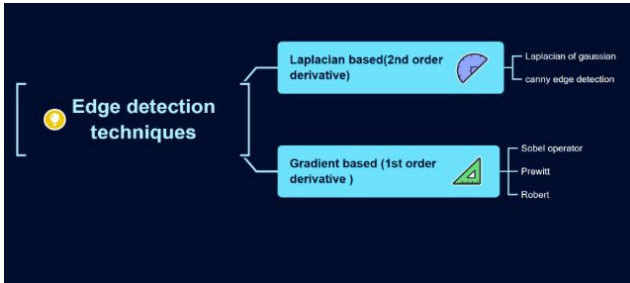


Figure-2. Methods of edge segmentation.

We used the Robert edge operator, Prewitt edge, canny algorithm, on one of the Alzheimer's patients, and the resulting Figures 3, 4, 5 show an intriguing outcome.

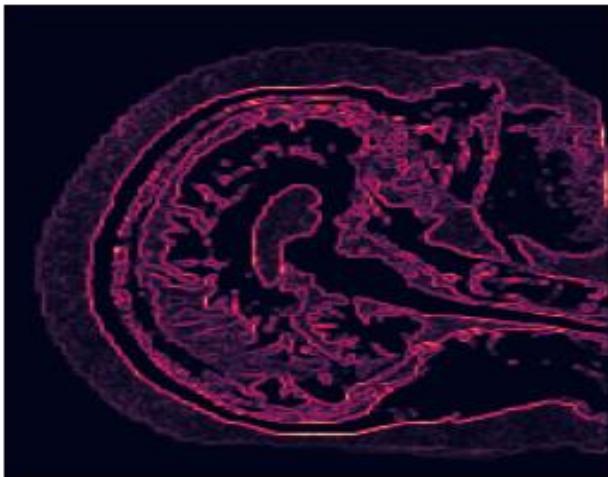


Figure-3. Applying Roberts Edge operator.




Figure-4. Applying Prewitt edge operator.

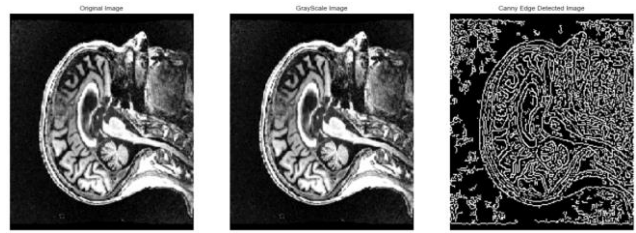


Figure-5. Applying Canny Algorithm for Edge Detection.

By using the Sobel edge detector, Figure-6 analyses the X-axis, Y-axis, and XY-axis edge detection in two different configurations. The second derivatives of a picture are compared using the Laplacian edge detector. It keeps track of how frequently the first derivative is altered in a single pass in Figure-7.

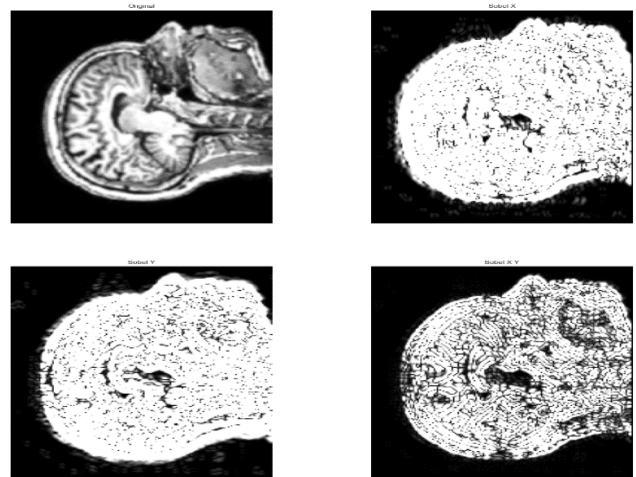


Figure-6. Sobel edge detector: Three different scenarios to compare the X-axis, Y-axis and XY axis edge detection.

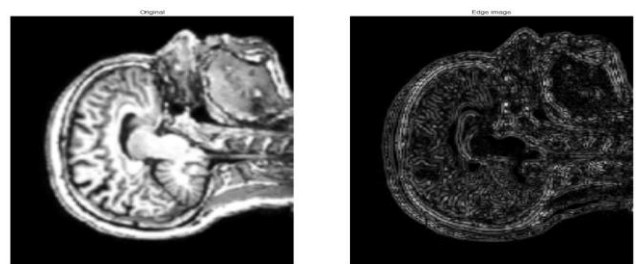


Figure-7. Laplacian edge detector of an Alzheimer's patient.

To eliminate weak edges, Canny edge detectors employ local minima and maxima for edge gradients in non-minimum edge suppression. By taking the local minima and maxima of the grey level intensities themselves, we can also utilise this to filter out noise. Finding local peaks and minima on the time series for random noise in Figure-8.

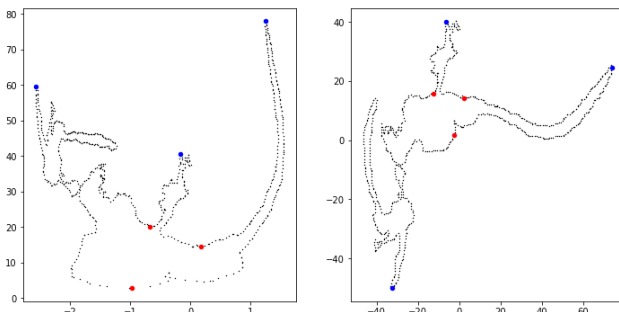


Figure-8. Plotting a graph to represent random noise.

6.3 REGION-BASED SEGMENTATION

The foundation of region-based approaches is the homogeneity principle, which states that pixels with similar characteristics should be grouped to produce a homogenous region. The majority of the time, a pixel's grey level serves as the criterion for homogeneity, and the following requirements can be used to define this criterion. $Re1 \cup Re2 \cup Re3 \cup \dots \cup Rei$ Where $Re1, Re2, Re3,$ and $Rei = I$ Rei are the area in Image I , while $Re1$ through $Re3$ are further regions.

According to homogeneity set theory, this is the case. Based on the idea that regions grow, region-based segmentation is further separated into three categories as follows:

6.3.1 REGION MERGING

The segmentation outcomes in this method depend on the choice of seeds; some seeding points are needed to start the process. Depending on the merging criterion, contiguous pixels are merged to grow regions iteratively. Until all pixels are assigned to their appropriate regions following the merger criterion, this process is repeated.

6.3.2 REGION SPLITTING

The full image is constantly split according to a principle that is the exact opposite of area merger until no more splitting of a region is conceivable.

6.3.3 SPLIT AND MERGE METHOD

This is a split-merge combo that makes use of the advantages of both techniques. This method, which divides an image segment into four quadrants if the original segment's attributes are not uniform, is based on the quad quadrant tree representation of data. After that, based on how uniformly the area is distributed, the four adjacent squares are combined (segments). Up until there are no more splits or merges left to do, this operation is repeated.

In addition to the strategies discussed above, watershed segmentation based on topography and hydrography is another method. In this instance, the K-mean clustering algorithm has been employed to group the pixels with comparable grey levels. The drawback of region-based segmentation is the potential for both under- and over-segmentation of image regions. However, there are two approaches to fixing this issue. For this, numerous

algorithms leveraging artificial intelligence approaches have been developed by carefully choosing the segmentation criterion.

7. BRAIN MRI IMAGING

White matter diseases like multiple sclerosis, progressive multifocal leukoencephalopathy, leukodystrophy, and post-infectious encephalitis can all be found using magnetic resonance imaging (MRI). Contrarily, a CT scan is unable to reveal white matter anomalies. The T1 and T2 relaxation durations are the main factors of signal intensity and contrast in MRI images of the brain. The contrast on T1 and T2 weighted pictures is noticeably different. Brain disorders have some signal properties as well. Pathologic lesions can be divided into five main types based on the distinct signal properties of the two fundamental images, T1- and T2-weighted A key indicator of brain atrophy in aging and neurodegenerative illnesses is the total brain volume (TBV). Because they are more effective, dependable, and reproducible, automated methods are chosen. For MR images, numerous automatic segmentation techniques are widely used in the clinical field. Techniques for segmenting MRI scans to determine the total intracranial volume (TIV) and total body volume (TBV) from images without observable disease were not fully verified. MR images were segmented using Free Surfer (<http://surfer.nmr.mgh.harvard.edu>). They did not validate TIV or TBV, only the ventricular CSF's correctness. MRI - 3D view was employed in our tests to provide a qualitative appraisal of our work. With a combination of multiple datasets and multi-task learning techniques, the method classifies voxels and their neighbours using 3D patches CNNs.

8. METHODOLOGY

Cover all of the image's pixels collectively or a group of image-extracted contours. Regarding some qualities or computed features, like colour, intensity, or texture, every pixel in the region is equal to every other pixel. Noise reduction is a popular pre-processing technique to improve the results of later processing. The neighbouring pattern, known as the window, moves over the entire signal entry by entry. The filter improves the MRI image quality.

The partitioning of the digital age into various segments is known as segmentation. The fundamental goal of our research is to be able to anticipate AD previously the signs are noticed by the clinician. To extract features from longitudinal MRI examination, we employed mixed-effects models. Then, before clinical occurrences, we used the attributes in deep learning models to forecast CN and AD. Features selection and model creation are the two main components of our technique. Image enhancement is the first step in image processing before pre-processing, which increases the image's quality and sensitivity by removing noise and redundancy without altering the image's information. Grey-level images are processed using different layers of a decoding convolutional neural network based on the intensity values of the image.

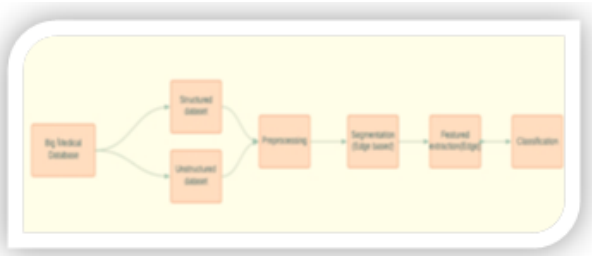

Figure-9. The proposed workflow architecture.

In this research, we take a step forward by analysing the noise reduction convolutional neural network's structure to squeeze the evolution into an extremely deep construction and to learn algorithm rules and regulatory techniques in the image to accomplish noise reduction. Figure-9 depicts the entire workflow for the suggested method. Free surfer is an automated technique that specialists use to help with segmentation. Hippocampal medial axis length and average thickness were determined using different manual and deep automated techniques. The hippocampus surface area and volume were determined using voxel-based proprietary software (MRI -3D view). A crucial component of a model is a 3D geometric model that simultaneously defines an object's skeleton and border. Even though medial axes are typically discussed for 2D objects, such as skeletons, we are working with 3D objects here. The medial axis (skeleton) in 3D is made up of a surface or collection of surfaces. The idea can be applied to three dimensions, where a collection of surfaces known as manifolds define the medial axis. The object is uniformly thinned until a curve, or group of curves, is left, and this creates the medial axis. The thickness of a structure can be determined from morphological parameters such as the distance from the medial axis to the boundary.

9. MEASUREMENTS

Definitions of calculated and obtained measurements that are utilised in statistical analyses of longitudinal and corrective data are provided below. TBV The total brain volume for each method was calculated as WM + GM. Atrophy TBV is determined as the picture's average TBV for FS and SPM. The distinctions between the reference and ICV estimations were computed using the ICV calculated ICV reference. A higher score on the MMSE Mini-mental State Examination (Folstein *et al.*, 1975) indicates stronger cognitive function; the highest score is 30 (28.64 1.38). The suggested technique for categorizing and segmenting the hippocampus in CN patients with AD. All MRIs were manually segmented, to put it briefly using both OASIS and ADNI datasets. The hippocampus volume and surface area were determined with the use of voxel-based custom software (MRI 3DView). Even though medial axes are typically used to describe 2D objects while we are dealing with 3D things, the terms "skeleton" and "medial axis" are interchangeable. The idea can be applied to three

dimensions, where a collection of surfaces known as medial manifolds define the medial axis. Different hippocampus volume normalizations have an impact on the relationship between schooling and cognition. when the left or right hippocampus volume is normalized using the ICV. Here, we compare the calculated total intracranial volume to the normalised whole brain volume in Figure-10.

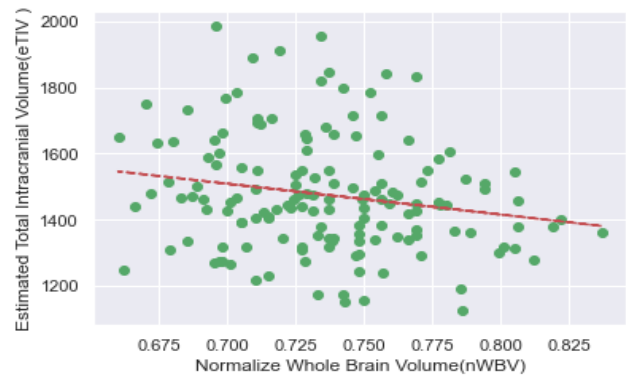


Figure-10. Draw scatter plot between EDUC and SES.

9.1 HIPPOCAMPUS VOLUME AND SURFACE AREA CALCULATION

In Alzheimer's disease, hippocampal volume and surface area is a sign sensitive to disease stage and progression (AD). In this research, the most important characteristics linked with AD and MCI patients were estimated for each participant's hippocampal volume and surface area. By multiplying the voxel size by the overall number of voxels present in the hippocampus, the volume of the hippocampus is determined. The hippocampus' surface area is determined by multiplying the pixel size by the overall number of surface pixels.

10. CLASSIFICATION

Convolutional networks are extremely appealing because they can extract a hierarchy of progressively sophisticated properties. This is accomplished by employing the convolutional layer's output feature maps as input channels for the following layer. Based on the structural differences in the hippocampus between AD and CN patients, the categorization features were chosen. Each participant was represented specifically as two sets of three-dimensional objects (left and right hippocampus). For image processing, a variety of classifier techniques have been applied. To perform a segmentation labels prediction. The last convolutional hidden layer is connected to a convolutional output layer, which is then followed by a nonlinearity layer (no pooling performed). Using Table-1, we summarise Alzheimer's patient classification using several datasets. And as shown in Table-2, we may compare the performance of SVM, Decision tree, Random Forest and CNN.

**Table-1.** Classification of Alzheimer's patient using different dataset.

Dataset	Plane	Sensitivity	Precision	Specificity	F-measure	Accuracy
ADNI	Coronal	99	98	98.30	99	98.2
OASIS	Coronal	93	97	93	95.01	97

Table-2. Classification comparison analysis of SVM, Decision tree, Random Forest and CNN.

Model	Accuracy	Recall	AUC
SVM	74	75	75
Decision tree	80	67	80.6
Random Forest	78	67	78.21
CNN	98.2	99	99

10.1 EXPERIMENT

11. UNSTRUCTURED DATASET

The Alzheimer's disease Neuroimaging Initiative (ADNI) is a multicenter longitudinal study that aims to create biomarkers for the early identification and monitoring of Alzheimer's disease using clinical, imaging, genetic, and biochemical methods. Under the direction of Dr. Michael W. Weiner, ADNI was established in 2004 as a private public partnership with \$27 million provided by 20 firms and two foundations via the foundation for the National Institutes of Health and \$40 million provided by the National Institute of Aging [11]. We made advantage of the MRI images from the ADNI database for unstructured database. The main objective of ADNI has been to determine whether serial MRI, PET, other biological markers, clinical evaluation, and neuropathological assessment can be coupled to track the development of MCI and early AD [12].

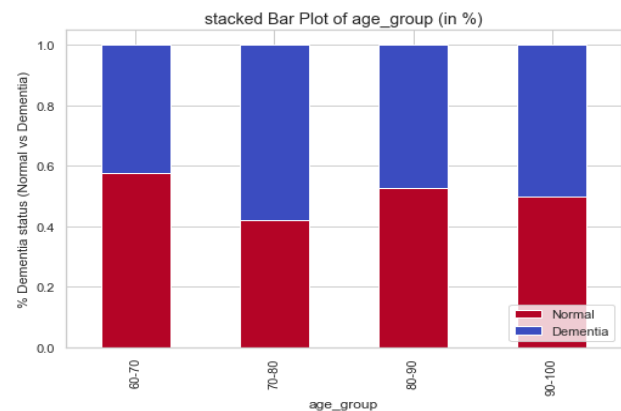
11.1 STRUCTURED DATASET

The open access series of imaging studies (OASIS) is a collection of magnetic resonance imaging (MRI) of human brain datasets that are publicly available. The longitudinal magnetic resonance imaging (MRI) data from OASIS has been used for the development of the system. eight different attributes: M/F, age, years of education (EDUC), socioeconomic state(SSE), mini-mental state(MMSE), estimated total intracranial volume (eTIV), normalized whole brain volume (nWBV), atlas scaling factor (ASF) have been considered for the final outcome.

12. RESULTS

Comparing the estimated intracranial volume (ICV) to the reference segmentations allowed researchers to look into biases related to gender, atrophy, or estimated skull size (as defined by the segmentation measure). The possible effect of ICV on relations between normalized hippocampal volume and traits including age,

education, and memory was evaluated by normalizing hippocampus volume using different ICV measures. Total intracranial volume (TIV) measurement is widely used to account for variations in pre-morbid brain size when examining the cerebral structures in Alzheimer's disease utilising imaging (AD). The (Total brain volume) TBV/ Intracranial Volume (ICV) ratios were dramatically lowered; the ICV and TBV measurements were compared favourably with values obtained by other study groups. Finally, based on the morphological features of the hippocampus, classify the AD and Normal Control (CN) groups using deep learning algorithms. In Figure-5, we compare the normal with a dementia patient in Figure-11.

**Figure-11.** Percentage of dementia status vs age group.

12.1 HIPPOCAMPUS SEGMENTATION RESULTS

The total subjects from different classes (AD and CN) were used, and the hippocampus was manually segmented and demarcated by experts. The volumes of the right and left hippocampus are computed and added.

Using MRI-3D view software, we compared the results to determine the hippocampus volume and surface area.

Hippocampal volumetry= voxel size *total no. of voxel
The surface area of the hippocampus =pixel size * total number of surface pixel

TIV is a parameter that is frequently employed in imaging studies of the cerebral regions in AD to compensate for changes in pre-morbid brain size. Moreover, all features were estimated from the segmented hippocampus. Due to the small number of participants in this study, we were unable to undertake an age and gender-matched comparison between the AD and CN groups. However, the data from both users clearly show that hippocampus volume, surface area, medial axis, and



thickness have reduced in AD individuals. When the statistical means of patients with AD and the normal control group are compared, the feature values in both situations differ significantly. All steps of the classifying process are automatic. We employed a GPU platform for our research, which has 3,840 cores running at 4608 GHz. is aNvidia model. Intel Xeon Silver 4110-2.1GHz-3.5GHz*8 cores HPC with GTX1080Ti Pascal chipset.

13. DISCUSSIONS

We demonstrate how CNN may be used for various segmentation tasks. CNN's deep architecture, which enables the extraction of a distinguishing feature's various levels of abstraction, is its primary strength. For a deep CNN, substantial computational and memory resources are required.

We have developed flexible constructing prediction models from longitudinal MRI and cross-sectional data in relation to cognitive aging and AD based on mixed-effects models and deep learning techniques. In this research, we used both deep learning and machine learning algorithms to distinguish the normal control group and Alzheimer's disease based on hippocampus morphological traits. Because manual hippocampal segmentation procedures are more accurate than any semi-automatic or automatic segmentation algorithms currently in use, we included them in our methodology. Segmentation accuracy has a direct impact on the values of the morphological characteristics during feature calculation. Using the voxel-based proprietary software (MRI -3D view) framework and deep learninghippocampal morphological features were extracted and classified to assess the volume and shape changes in the hippocampus between the AD and the healthy control group. According to the study's findings, the hippocampal region's shrinkage and shape alterations have a strong association with Alzheimer's disease. Our classification findings demonstrate a connection between

morphological abnormalities in the hippocampus of AD. The amount of brain tissue, cerebrospinal fluid, and other components that are contained within the skull during childhood determines the total intracranial volume. Early childhood is when the brain volume reaches its peak, and it starts to deterioration around initial adulthood. Our measurement of TIV is probably going to have a strong relationship with premorbid brain size and be largely unaffected by the onset of a disease or aging the benchmark in repeated segmentation using ICV was shown to be extremely reliable. Visual inspection revealed that all structures identified by the reference segmentation technique were included in the segmentation done with different inbuilt software. Both techniques overstate ICV in this research. The normalised volume will have an error that corresponds to the ICV error. Based on measurements of the hippocampus and lateral ventricles volume in a single patient over time, we were able to predict the change from cognitively normal (CN) to Alzheimer's disease (AD). Prior to the comparable clinical diagnostic, it is difficult to say how early we can recognise the risk of AD before a diagnosis. There are several restrictions linked to the data material that was accessible for our research and our methodology. Alzheimer's disease clinical diagnosis is intrinsically uncertain. By computing the volumes of the hippocampi and lateral ventricles using voxel-based proprietary software (MRI -3D view), we investigated some of the inherent variations that happen when using various software versions and when the images are captured on scanners with various magnetic field strengths. Biochemical testing, genetic analyses and other clinical or laboratory measurements can all be incorporated. We evaluated the performance of pre-trained CNNs trained wholly from the search using medical imaging data for each application. In this research, we carefully examine the transfer of knowledge to medical imaging. In Table-3, we briefly describe the hippocampus criteria for CN vs normal.

Table-3. Comparison analysis of Hippocampus.

Group	Number of subjects	TIV	Hippocampus volume	Hippocampus thickness	Hippocampus area
CN	69	1515	6880	9.18	2809
AD	72	1318	6215	8.48	2455

14. CONCLUSIONS

One of the characteristics of big data analytics that we emphasize in our research is variety. The recently created algorithms were tested using actual medical data from the OASIS and ADNI databases. Each slice was processed by the system to separate the ventricles, and the results were examined visually and contrasted with the original images. Edge detection techniques are with thresholding to extract the ventricles and remove unnecessary regions. Different relationships between education and cognition were identified in research where hippocampus volume was standardized with ICV, reliant on the ICV quantity utilized. Therefore, it is demonstrated

that the results of a morphological investigation may be impacted by the method choice for ICV estimation. When choosing an ICV estimate method for research that includes measurements of brain volume, this should be taken into account. With the different machine and deep learning methods, which are used to segment the region and extract the volume for comparison purposes, The CNN model for the HC area is found to perform better when categorising AD from normal phases like CN, with an accuracy rate of 98.2%. The result in an excellent performance for the proposed method, according to the paper's conclusion.



REFERENCES

- [1] Jenkins R., Fox N.C., Rossor A.M., Harvey R.J. and Rossor M.N. 2000. Intracranial volume and Alzheimer disease: evidence against the cerebral reserve hypothesis. *Archives of neurology*. 57(2): 220-224.
- [2] Deepa V., Benson C.C. and Lajish V.L. 2015. Gray matter and white matter segmentation from MRI brain images using clustering methods. *International Research Journal of Engineering and Technology (IRJET)*. 2(8): 913-921.
- [3] Gopal N.N. and Karnan M. 2010, December. Diagnose brain tumor through MRI using image processing clustering algorithms such as Fuzzy C Means along with intelligent optimization techniques. In 2010 IEEE international conference on computational intelligence and computing research (pp. 1-4). IEEE.
- [4] Salehi W., Gupta G., Bhatia S., Koundal D., Mashat A. and Belay A. 2022. IoT-Based Wearable Devices for Patients Suffering from Alzheimer Disease. *Contrast Media & Molecular Imaging*.
- [5] Pattanayak B.K., Nohur D., Cowlessur S.K. and Mohanty R.K. 2021. An IoT-Based System Architecture for Environmental Monitoring. In *Progress in Advanced Computing and Intelligent Engineering* (pp. 507-514). Springer, Singapore.
- [6] Pattanayak B.K., Hota N. and Mishra J.P. 2021. A Systematic Overview of Fault Tolerance in Cloud Computing. *Intelligent and Cloud Computing*. pp. 13-21.
- [7] Van Schie K. and Anderson M.C. 2017. Successfully controlling intrusive memories is harder when control must be sustained. *Memory*. 25(9): 1201-1216.
- [8] Carmo D., Silva B., Yasuda C., Rittner L. and Lotufo R. 2019. Extended 2D consensus hippocampus segmentation. arXiv preprint arXiv: 1902.04487.
- [9] Natarajan P., Krishnan N., Kenkre N.S., Nancy S. and Singh B.P. 2012, December. Tumor detection using threshold operation in MRI brain images. In 2012 IEEE international conference on computational intelligence and computing research (pp. 1-4). IEEE.
- [10] Matoug S. and Abdel-Dayem A. 2012, February. Implementation of Segmentation Methods for the Diagnosis and Prognosis of Mild Cognitive Impairment and Alzheimer Disease. In *Journal of Physics: Conference Series* (341(1): 012020). IOP Publishing.
- [11] Lin W. 2020, September. Synthesizing missing data using 3D reversible GAN for alzheimer's disease. In *Proceedings of the 2020 international symposium on artificial intelligence in medical sciences*. pp. 208-213.
- [12] Duarte-Guterman P., Albert A.Y., Barha C.K., Galea L.A. and Alzheimer's disease Neuroimaging Initiative. 2021. Sex influences the effects of APOE genotype and Alzheimer's diagnosis on neuropathology and memory. *Psychoneuroendocrinology*. 129, p. 105248.